



Alexis LACOUT

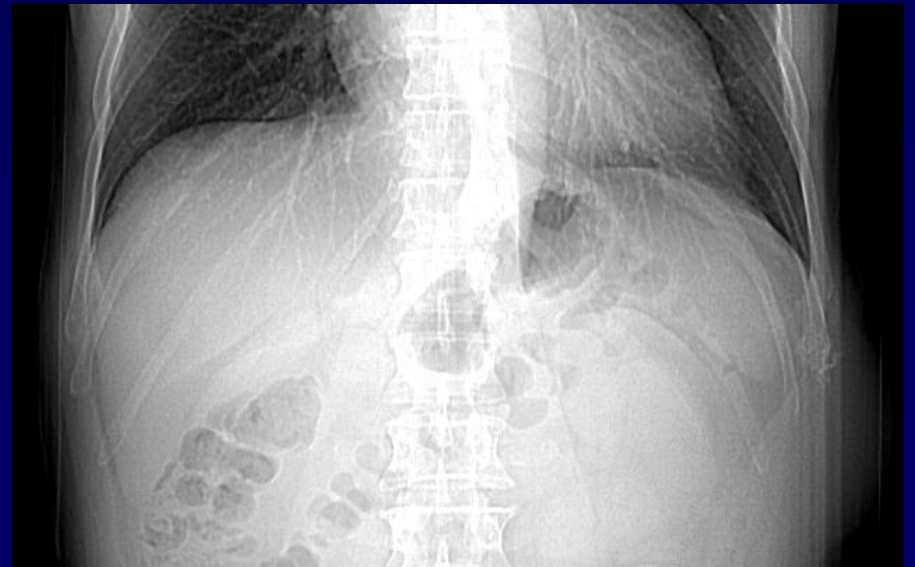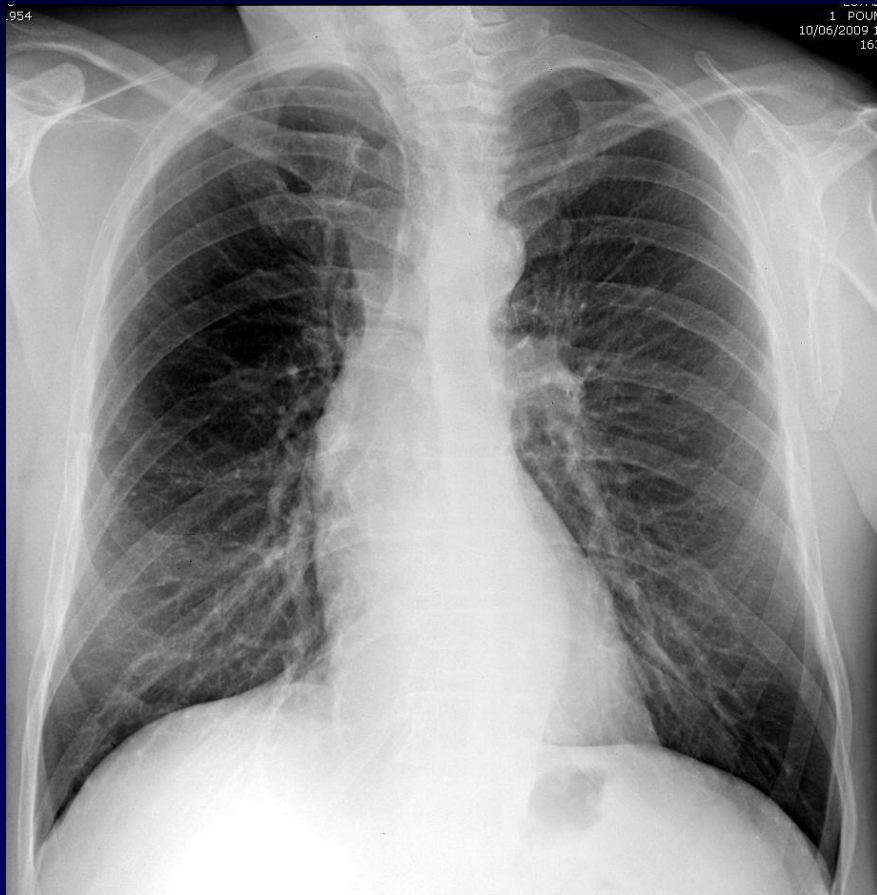Homme de 54 ans

Tuméfaction pariétale gauche

Augmentation lente et progressive de volume

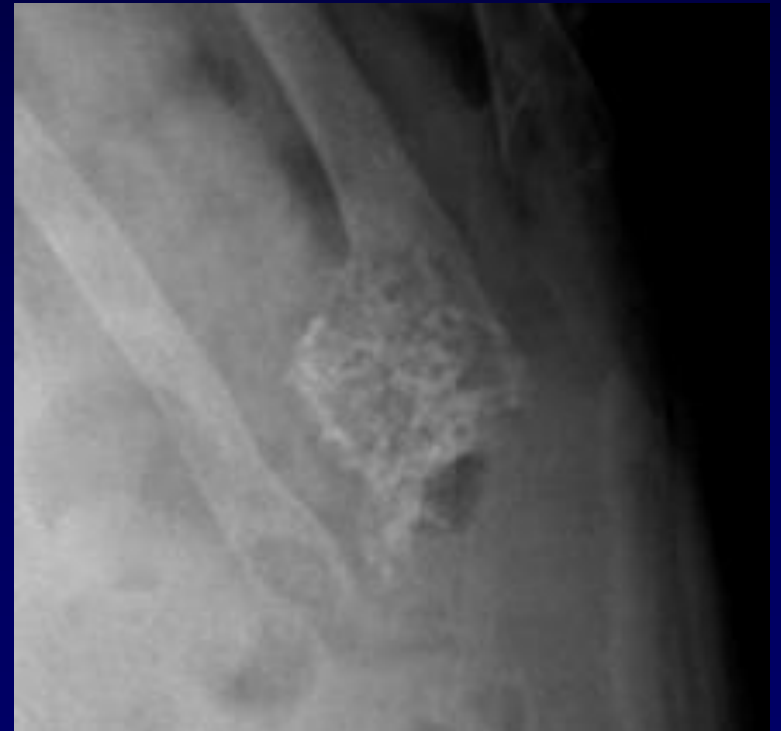
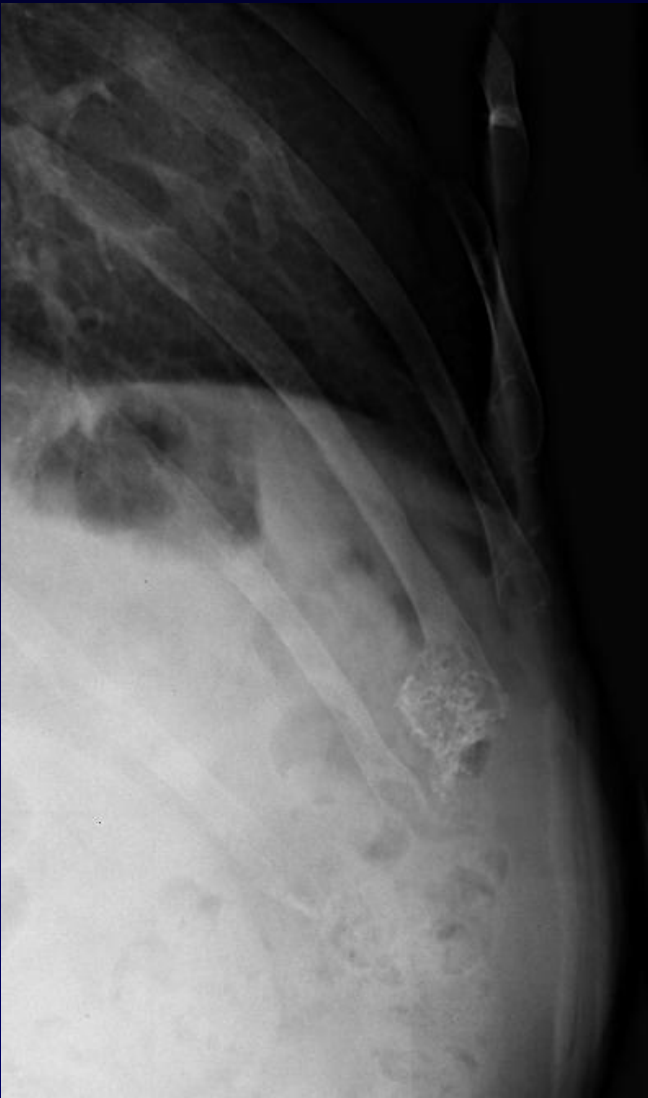

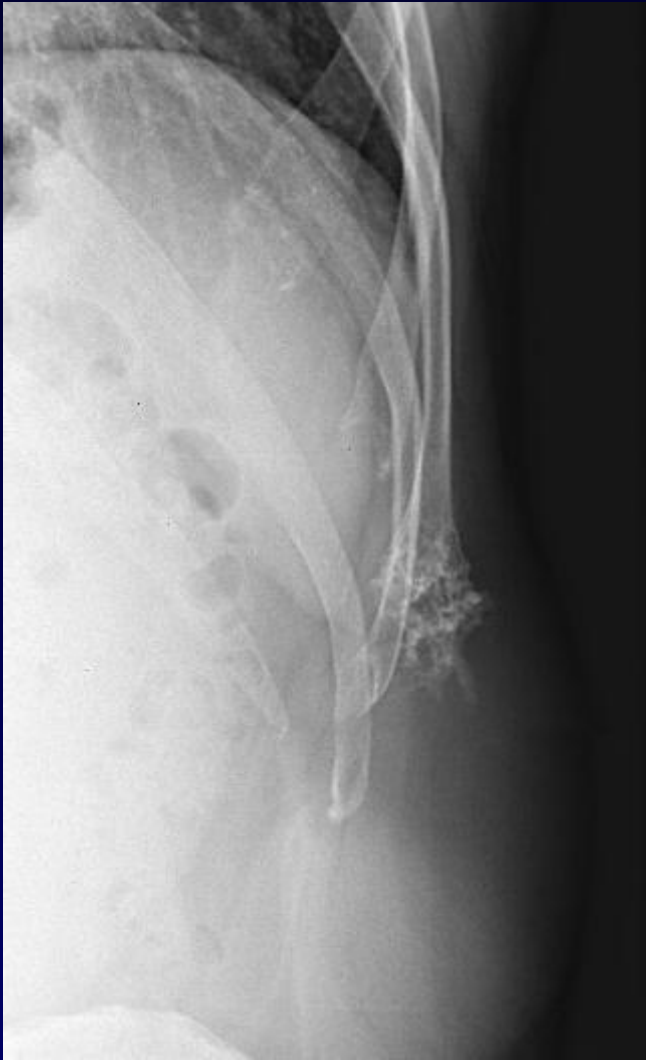# Radiographies du thorax



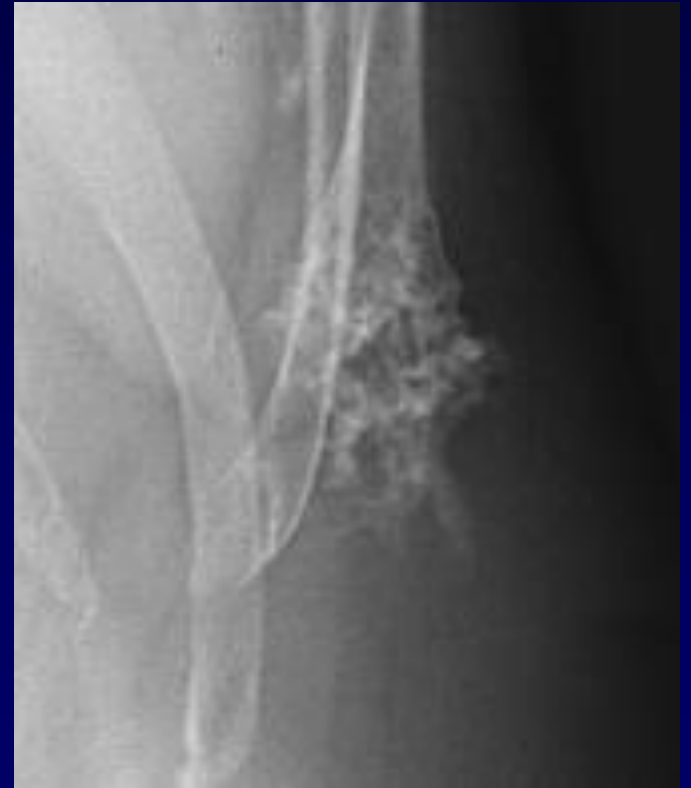

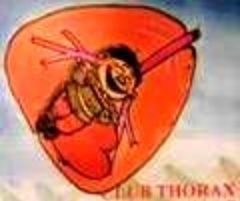# Radiographies du grill costal



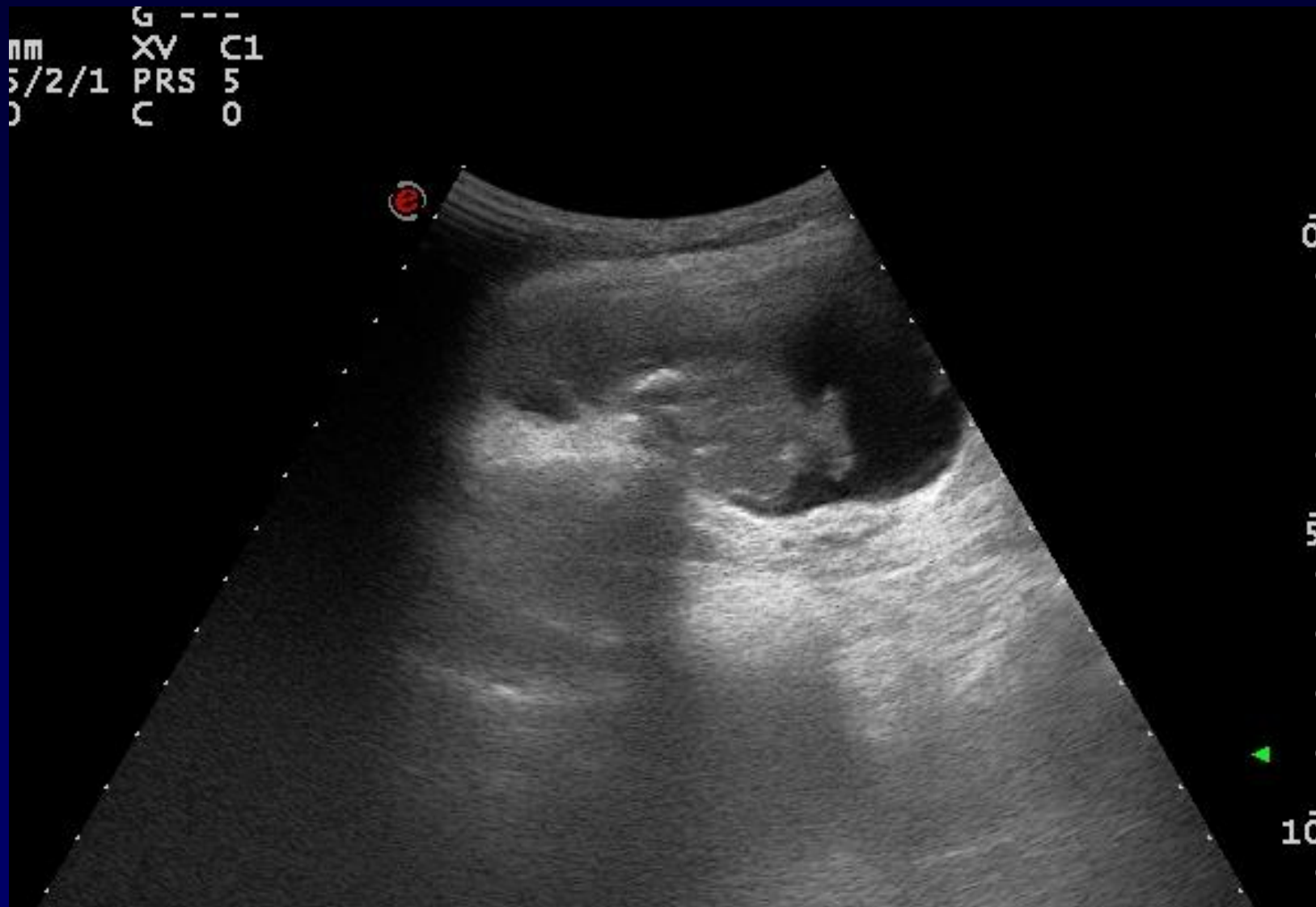


## Radiographies du grill costal



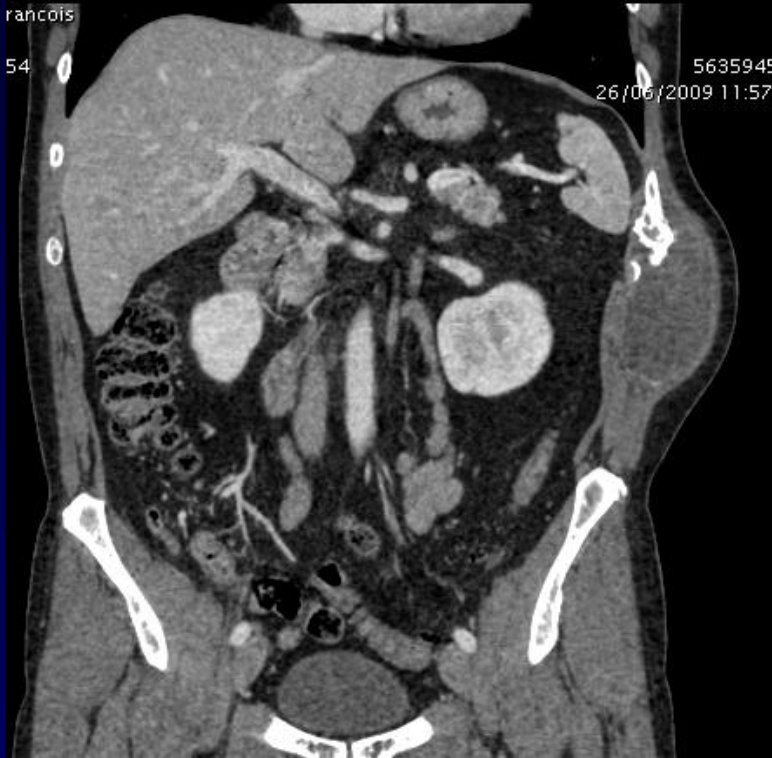


# Echographie

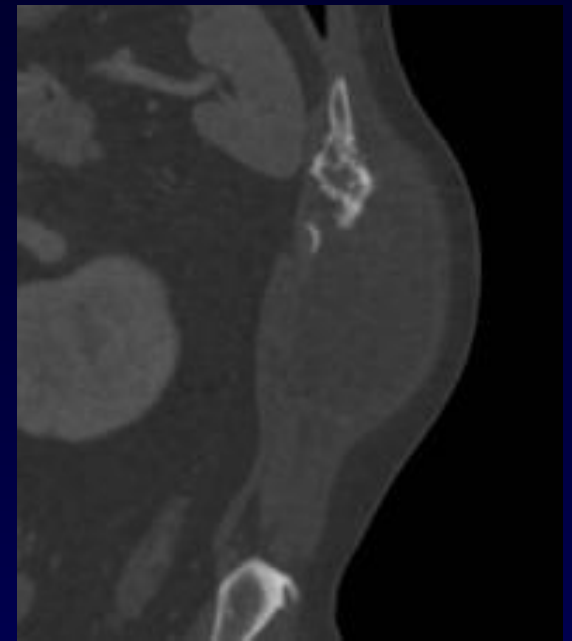




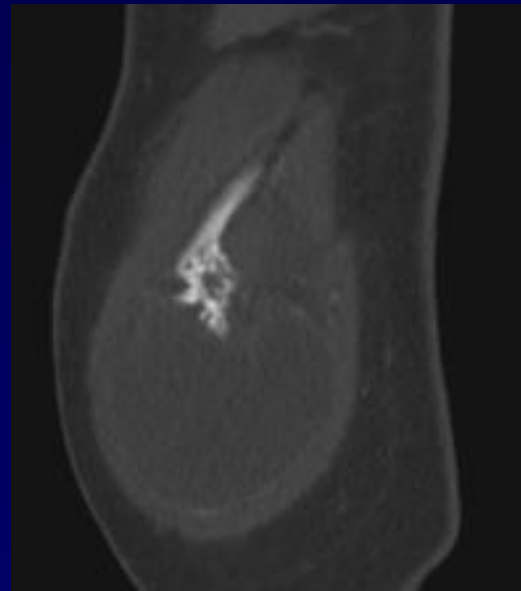
# Scanner



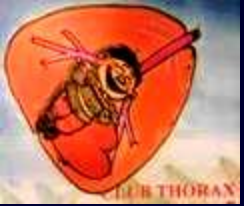Coronal



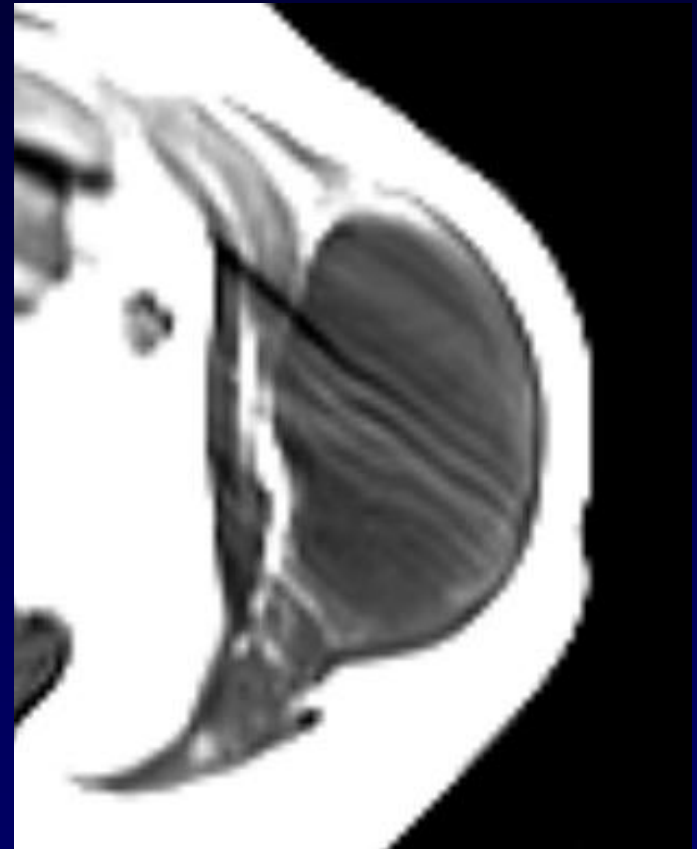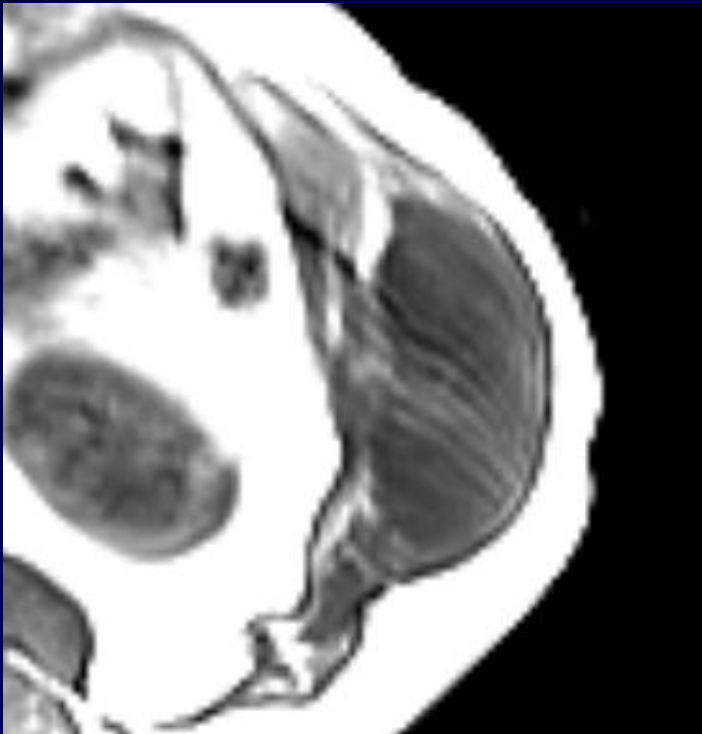
Coronal



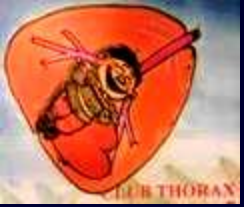Sagittal



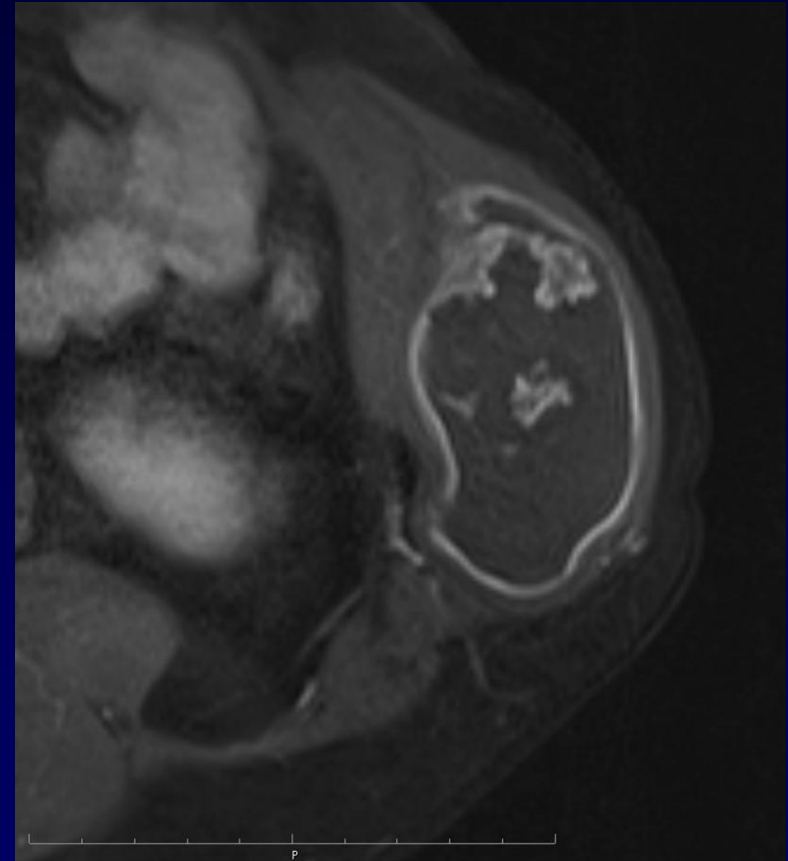
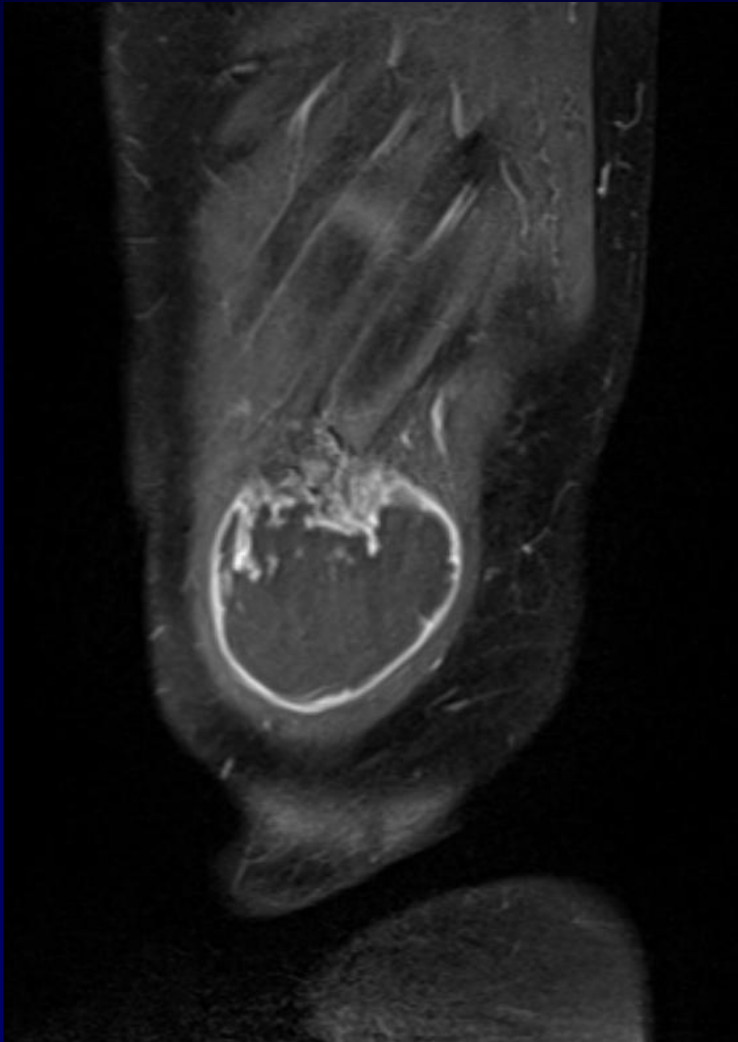
IRM



Axial T1



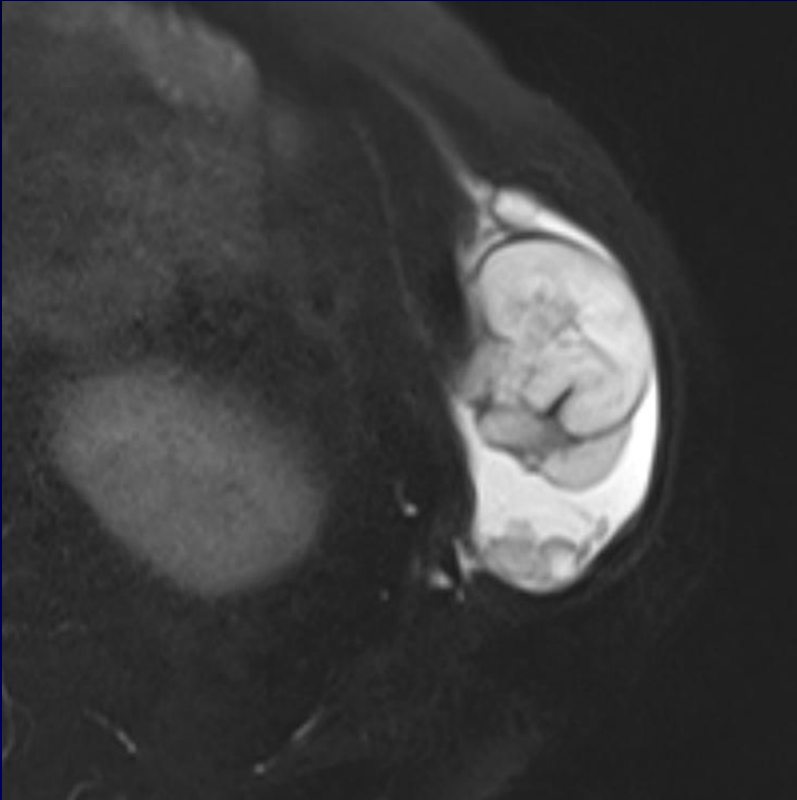
# IRM



Sagittal et axial T1 gado Fat Sat



IRM (enfin le T2!...mais on avait le diagnostic sur la RT)



Axial et coronal T2 Fat Sat



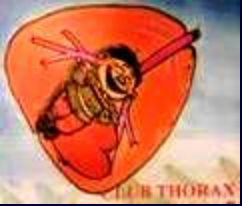

**Diagnostic ?**

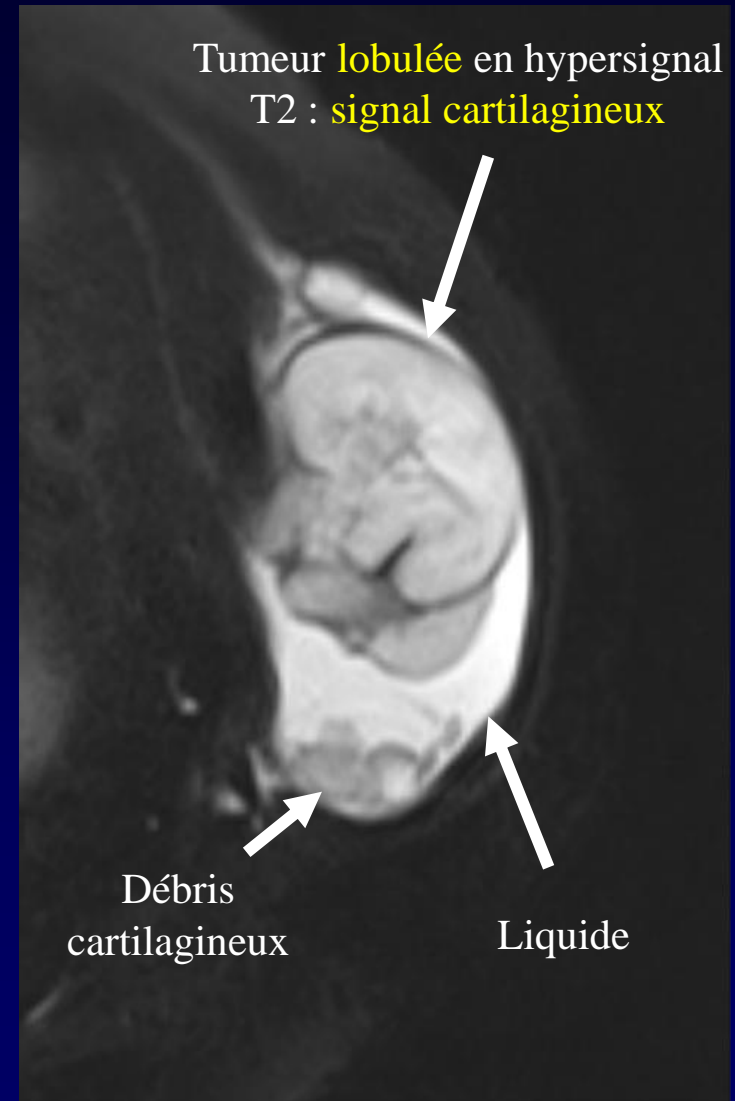
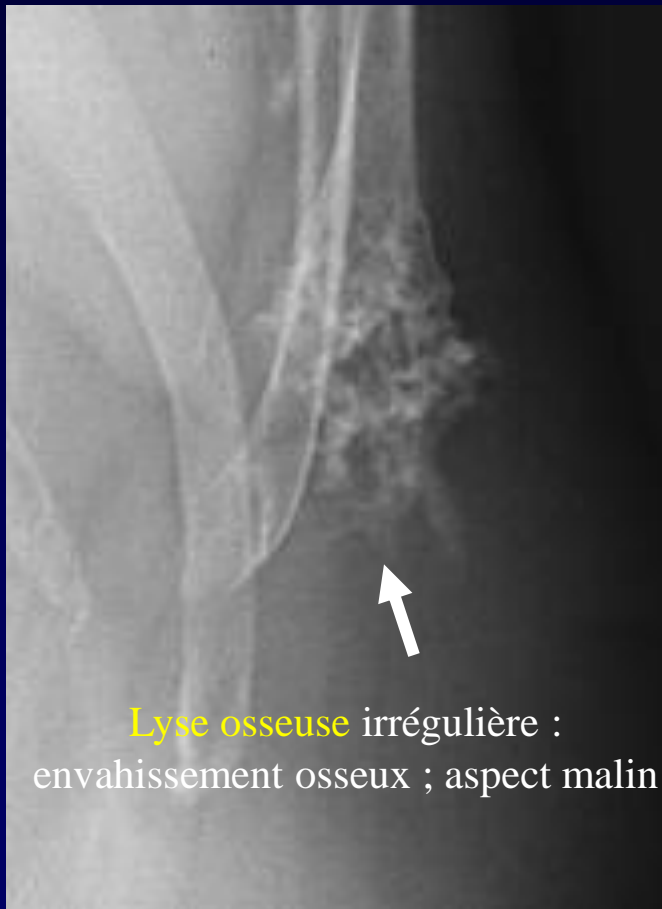


# Diagnostic

**Probable chondrosarcome costal**



# Siège de la lésion à la jonction costo - **chondrale**



**Importance du T2**